

# Spontaneous Release by Positioning

Lawrence Hugh Jones, D.O., Ontario, Oregon  
The DO, Jones LH. 1964; 1:109-116

Discovery of what appears to be a new principle of lesion production has resulted in a simple, easy method of correction without the use of force.

Undoubtedly many osteopathic physicians have observed occasional cases of spontaneous lesion correction. Probably most of them have shrugged and wished that all lesions might be corrected so easily – but that it is a one-in-a-thousand phenomenon and not worth thinking about, just a fortunate combination of influences.

Most osteopathic physicians can remember some case that was seemingly impossible; a case that resisted all their skill, diligence, and ingenuity, and continued to defy their best efforts again and again until only stubbornness kept them from admitting they were stumped. Each visit became a maddening frustration. Suppose that after months the disorder one day spontaneously corrected completely and easily before their eyes.

This background of frustration is included because it furnished the necessary inspiration for 10 years of experimentation.

The ease and effectiveness of this technique and the revolutionary concept it entails are very difficult to believe by osteopathic physicians who have accepted as necessary the use of certain amount of force to attain a correction on hundreds of thousands of lesions in their regular practices. Yet, demonstrations in seminars in the western states have shown most of the osteopathic physicians attending that the technique is practical for them on their first or second attempt. They are convinced only after feeling it happen under their own fingers or on their own lesions.

## BACKGROUND

In the original case a fortunate combination of accidents made the correction possible. A man had had a very severe and painful second lumbar lesion with psoasitis for a long period, and I had been unable to correct it despite maximal efforts. He had complained of being awakened every few minutes during the night by his pain. I was devoting an entire treatment period to finding, if possible, a position of relative comfort which he might use to secure rest without heavy sedation.

We finally found a position which achieved a high degree of comfort, but it was astonishingly extreme. It was unbelievable that such a rigid patient could tolerate, let alone enjoy, such a position. He was nearly rolled into a ball, with the pelvis rotated about 45 degrees and laterally flexed about 30 degrees.

The patient was so well relieved that he was propped up and left in the position while I treated another patient. When I returned and restored him to a normal position, he remained comfortable. Examination revealed an excellent correction of the lesion, with marked improvement in free mobility and two-thirds reduction in pain and tenderness. To accomplish a correction so easily in a case so desperately “impossible” was hardly believable. It was too impressive to be ignored.

Experimentation was begun on other second lumbar lesions. Many were corrected in positions similar to the one that had been effective for the first man. Most of the others responded to minor modifications of the original position. Experimentation seemed relatively safe, because no force was necessary and a position which brought immediate comfort could hardly be construed as an injury. Gradually the time of support in the position of release was reduced from 20 minutes to 10 and then 5. Success continued down to a period of 90 seconds. Below this time, success was irregular, even though we achieved an excellent position for relief of pain and tenderness in the lesioned joint. It still appears to be the minimum, though probably some skilled technicians will be able to reduce it further.

Success with second lumbar lesions encouraged attempts on other lesions. Some results were gratifying, others disappointing, but little by little it became clear to me that all osteopathic lesions will correct spontaneously in a position of release, and that a large proportion of lesions of a given joint will follow a pattern of position common to other lesions of that joint.

During this time the position of release and comfort was found in a high percentage of the cases to be simply an exaggeration of the abnormal bony relationship found upon examination. This has occurred so consistently that I have accepted it as proof of diagnosis. On the occasions where the two do not agree, I distrust my diagnosis and rely on the position of release as both diagnosis and treatment.

## SOME APPARENT PRINCIPLES

Most lesions can be corrected in exaggeration of the diagnosed abnormal bony relationship. Occasionally diagnoses are not clear. We are saved from testing aimlessly by the fact that most lesions of any given joint are likely to follow a pattern. Through the years I have been able to accumulate a list of the more common lesions. In three fourths of the lesions in which the diagnosis was not clear, disorders were found to respond to positioning according to the directions on the list, with minor variations.

This list, which will be presented later, is offered not to be blindly imitated, but as means of saving the busy physician the time-consuming experimentation needed to develop it. He must never lose sight of the principle. The techniques are successful only if they achieve the position of relief of tenderness and pain. If unsure of his diagnosis, he tries the basic positions first. Then, if necessary, he abandons them and learns the effective position by trial and error, secure in the knowledge that there is such a position for each lesioned joint. After a few weeks of practice he will not need to delay long on any lesion.

Can this simple, easy method of correction be possible? How can it be, and yet have escaped the notice of thousands of osteopathic physicians all these years? Yet the first published reference I could find to any similar work done is a statement by Dr. Ira C. Rummey of Kirckville College of Osteopathy, in January 1963. In a summary of forces, which can be used to re-establish, normal spinal motion, he lists: "Inherent corrective forces of the body – if the patient is properly positioned, his own natural forces may restore normal motion to an area."

The phenomena demonstrated in this work indicate that the lesion formation occurred in a position much more extreme than the position in which we found the lesioned vertebrae upon examination. The patient had no pain in this extreme position. He reported, "It hurt when I started to straighten up." I hurt more as he continued to straighten. Muscles, which were relatively relaxed in the extreme position, tensed in an effort to splint this lesioned joint from further strain.

Is the muscular tension arranged so as to splint this joint, to prevent it from moving back into its eccentric position? No! The muscular tension resists any motion away from the extreme position in which the lesioning occurred.

Even the severest lesions will readily tolerate being returned to the position in which the lesion formation originally occurred, and only to this position. When the joint is returned to this position, the muscles promptly and gratefully relax. These joints do not cause distress because they are cooked; they are painful because they are being forced to be too straight. This is the mechanism of strain. This protective muscle splinting is the "bind."

The three schematic drawings of joints in Figures 1, 2 and 3 illustrate a normal joint in normal position, a normal joint in extreme position in which lesion formation occurs but not strain, and the joint as found by the physician in lesion and in strain. Muscular tension is not the result of muscle stretching or a reflex splinting to prevent return of the joint to the extreme position. It is the opposite. It is the reflex muscle splinting which prevents further movements away from the extreme position where lesion formation occurred.

In Figure 3, muscle "A" is splinted in chronic contraction. Muscle "B," though stretched, is not splinted or contracted. The effect is that the joint may easily move back to the extreme position which brings relief. Any movement away from the extreme position increases the strain and is resisted by increased splinting of muscle "A." To initiate a spontaneous correction, a relaxed patient is positioned so as to return the joint to the extreme position, hold it for 90 seconds, and return the still-relaxed patient to normal.

**DISCUSSION**

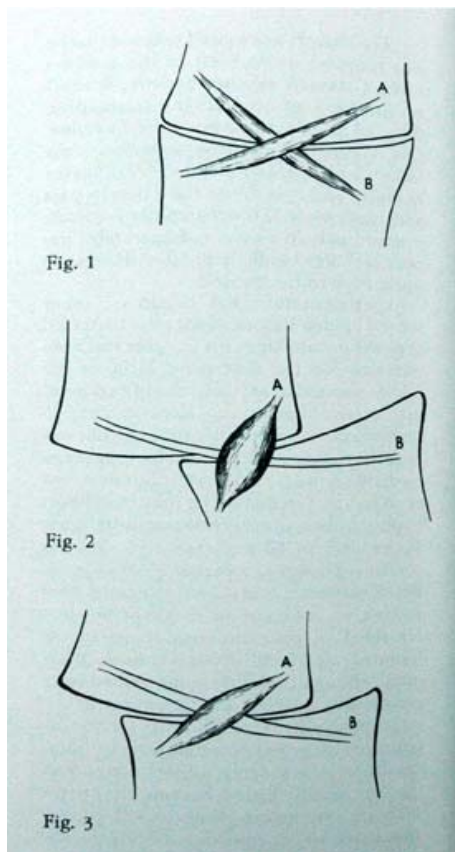
In the light of this knowledge, what happens to some of our concepts of the osteopathic lesion? Could exaggeration of a deformity bring immediate relief to a lesion if the main factor of that lesioning were strain of ligaments or other periarticular tissues or compression of the emerging nerve? It appears likely that exaggeration of the deformity would aggravate the pain in either case because of further overstretching of ligaments or compression of nerves. Local edema begins to resorb immediately upon achieving the position of release, but it requires some time. What "released," so that it could start to resorb? I still have no satisfactory explanation. Yet this new knowledge does upset many of the accepted concepts of the mechanism of producing and maintaining factors of the osteopathic lesion.

It would be a tremendous task to check each muscle and ligament involved in an osteopathic lesion to prove this theory.

However, we can reason backwards. The joint is rigid; periarticular tissues are tense. The joint seems to resist all motion. The position of greatest resistance and pain is a position opposite to that of the original abnormality. For instance, a lesion of left lateroflexion resists most violently a bend into right lateroflexion. On the other hand, even the most acute lesion will readily submit to passive movement in exaggeration of the diagnosed lesion, and in this direction only!

The physician palpates the tense lesioned area while moving the patient into a position of exaggeration. When he attains the optimum position, there is an almost instantaneous relaxation of tense tissues, which is so marked that it is palpable by any osteopathic physician with ordinary skill. At the same time the patient if questioned will report that "you took the pressure off." Localized edema is felt to start to "melt" immediately, but it requires many seconds for the effect to be complete. This perhaps is the factor requiring the 90-second support of the joint in the position of release to effect a correction.

The concept of tissue stasis in lesions seems to be borne out, but what was the instantaneous "catch" that started it, and where? For a long time the theory of deformity of the nucleus pulposus seemed secure. Yet the principles described apply as well to all appendicular lesions as to spinal lesions. Where was the "catch" there? What have we left? Something in or around the joint is "caught."



Exactly what it is, we do not know, but it occurs in a markedly eccentric position and goes into a strain pattern when pulled away from that position. It will correct itself spontaneously if it is supported in the original eccentric position and then is returned, still relaxed, to normal. Once the physician has attained the position of release, no further effort is necessary. Happily back out of the continuous strain it has been suffering, the joint can in 90 seconds restore its own normal function again.

### **SPECIFIC MYOFACIAL TRIGGERS**

Many patients complain of tenderness remote from the vertebral area. Since my philosophy has always been along the lines of specific lesion for a specific pain, I have always attempted to pin down an association between a certain pain and/or area of acute sensitivity with a specific lesion. But we find that many patients are so vague about the nature and distribution of their pains that from a practicing physician's viewpoint the areas of acute sensitivity prove to be much more reliable. There are the myofascial triggers.

These triggers are a valuable aid to diagnosis for any osteopathic physician and there are many fairly successful tricks of counter irritation used by some physicians in treatment. In this treatment by use of the position of release they are of inestimable value in eliminating guesswork.

For instance, in lower lumbar lesions it is easy to mistake paravertebral tenderness of a fourth for that of a fifth lumbar lesion; in many instances, tenderness close to the spine may be so mild as to dissuade the operator from giving either diagnosis much credence. On the other hand, their specific trigger points are inches apart and are so sharply sensitive as to remove all doubt of which lesion is the offender. Whereas the vague tension and tenderness near the spinal joint may give a relatively inconclusive manifestation of success in finding the position of release, pain at the trigger point dissolves as if it has suffered a power failure. The sudden definite release is so complete that the uninitiated patient will doubt that you are still probing the right spot. The physician knows his treatment is correct, and the patient also immediately knows.

Some of the triggers and maybe all have been known for many years. Works by Chapman, Travell, Judovich and Bates, and Yoshio Nakatani are extensive. The triggers offered here for your convenience are easily found and are definitely specific manifestations of specific lesions. Relief of the trigger point is accomplished only by relieving the causative lesion in the responsible joint.

Though we use the relief of tenderness in the trigger point as evidence of the correct position of release, we are treating not myofascial triggers but spinal lesions. Tension and tenderness near the spinal lesion are relieved simultaneously with relief of the trigger.

### **SPECIFIC TRIGGERS AND ASSOCIATED LESIONS**

Right sacroiliac: Different triggers are usually relieved by different methods (see suggested techniques). The upper trigger is 1 inch from the posterior spine of ilium, at 5 o'clock. The middle trigger is near the third sacral foramen, or about 2 ½ inches from posterior spine, at 7 o'clock. The lower trigger is just lateral to sacral cornu (associated with coccygeal pain and tenderness). The trochanter trigger is on the posterior superior surface of the greater trochanter of femur. The pubic trigger is on the superior margin of pubic bone 1 ½ inches lateral to symphysis. (These last two are used in treating a supine patient.)

Right fifth lumbar: The upper trigger is on the medial margin of ilium near the posterior superior spine. The lower trigger is in the notch just caudad to the posterior superior spine.

Right fourth lumbar: This trigger is about ½ inch posterior to tensor fascia lata and 2 inches caudad to the rim of the ilium.

Right third lumbar: This trigger is 1 to 1 ½ inches caudad to the anterior superior spine of the ilium or in tensor fascial lata. The posterior third lumbar trigger is a point 2 ½ inches lateral to the posterior superior iliac spine and 1 ¼ inches caudad to the iliac crest.

Right second lumbar: One trigger is on the lateral side of the middle of the right inguinal ligament. Another is on the anterior inferior iliac spine.

Right first lumbar: This trigger is ¾ inch below and medial to the anterior superior iliac spine.

Right twelfth thoracic: This trigger is on the inner border of the iliac crest, about 2 inches from anterior superior iliac spine.

Right eleventh thoracic: This trigger is on the inner border of the crest of the ilium in the midaxillary line.

Eighth and ninth flexion lesion: This is associated with tenderness 2 or 3 inches below the xiphoid process, and often with epigastric pain and ileitis. Paravertebral tenderness and pain here is often so slight as to be overlooked.

Third thoracic: This trigger is a point 2 ½ inches caudad to the spine of the scapula and 1 inch medial to the lateral border of the scapula.

Second thoracic: This is a point ½ inch above the spine of the scapula and 2 inches medial to the acromial process.

Second cervical: This trigger is just beneath the superior nuchal line, 1 ¼ inches lateral to the midline.

First cervical: The trigger is on the posterior border of the ramus of the mandible, ¾ inch above the angle.

Humerus: Affectations here appear to be actual lesions of the humeral joint, although different ones are often associated with the upper thoracic lesions as indicated. Treatment is directed to a position of release in the humeral joint (see suggested techniques). (1) The first

trigger is a point on the short head of the biceps 1 ½ inches below the coracoid process of the scapula (often associated with the first thoracic lesion); second is a point about 1 inch posterior to trigger above. (2) Another trigger is at the middle of the deltoid, 1 inch beneath the acromion (usually associated with a second thoracic lesion). (3) Another is on the posterior margin of the deltoid muscle, 1 ½ inches from the acromial process of the scapula (often associated with third thoracic lesions). (4) Another is deep in the posterior fold of the shoulder near the tendon of the teres major (often associated with fourth thoracic lesions). (5) The circumflex nerve trigger is about 1 ¼ inches below the spine of the scapula and 3 inches medial to the acromion.

Elbow lesion: Elbow tenderness is on the head of the radius or in the belly of the brachioradialis muscle (tenderness on lateral epicondyle usually is a trigger from first thoracic or first rib). Tenderness on medial epicondyle usually is a trigger from the fourth thoracic or the fourth rib, or a simple extension of the ulno-humeral joint.

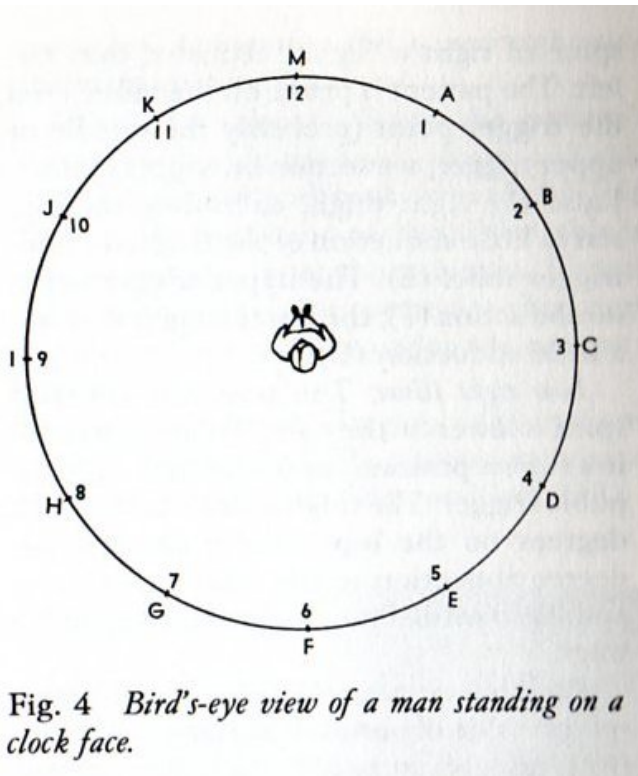


Fig. 4 Bird's-eye view of a man standing on a clock face.

#### BASIS OF SUGGESTED TECHNIQUES

A large proportion of spinal joint lesions will be found to follow a pattern. The majority of lesions of each joint tend to be lesioned in a position common to that joint. Though there are many atypical lesions that do not conform, the busy physician may save much time by checking out probable positions first. If successful, he has verified his positional diagnosis while making his correction.

However, he will encounter enough atypical or less common lesions that he will continually find it necessary to abandon the hope of the typical lesion and rely upon his own diagnosis of the position of the lesion. After diagnosing it he will exaggerate the position to the position of release. Occasionally the diagnosis will not be clear, and he will need to search by trial and error. This will not discourage him when he becomes certain that every osteopathic spinal lesion has a position of release and that by finding it he can produce a correction.

Contemplation of the thousands of possible positions may seem overwhelming until we reduce the consideration of the possible positions to their three basic elements. We need to consider only the direction of rotation and/or bend and how much.

1. Rotation can be only to the right (indicated by "R") or to the left (indicated by "L"). These are described according to the direction of rotation the body of the superior vertebra in relation to the body of the inferior vertebra.

2. Bending (use of such words as flexion and extension is avoided because they mean different things to different osteopathic physicians) can be toward any one of 360 degrees, but requirements for use here are only that we bend in a direction within 30 degrees of the ideal direction. Forward or backward bending is considered simultaneously with side bending as one bend, because it is one bend and not two as we are used to thinking of it.

Then, if we imagine our patient to be standing in the center of a large clock face which has been placed face up on the floor and standing so that he faces the mark of 12 o'clock (fig. 4), he may be considered to bend in the direction of any hour on the clock face. This will be accurate enough for effective practical use, though minor modifications may increase the effectiveness. For example, rather than to describe the position of a lesioned joint as right side bending and forward bending, we can say toward 2 o'clock. To further simplify for the purpose of record keeping, we substitute a letter for each hour and record a bend toward 2 o'clock as "B," or a bend toward 6 o'clock as "F," and so forth.

3. The amount of bend needed is quite uniform and can easily be learned with practice.

Now, since we have indicated rotation right as "R" and rotation left as "L," we can indicate a fourth lumbar lesion bent to the left side and backward and rotated to the left as "4L-HL." (Note that "M" is used at 12 o'clock rather than "L" to avoid confusion.)

Description of specific suggested techniques will include these symbols to indicate the influence brought to bear on the lesion under discussion.

In most cases the pelvis is thought of as if each side were swinging on the sacrum on a transverse axis. This does not cover oblique bends.

#### TECHNIQUES

High right ilium: The posterior superior spine of right is higher cephalad than the left. The patient is prone on the table. Find the trigger point (probably the middle or upper trigger; see section on trigger points). Raise the right thigh, extending the hip; start a little abduction of the thigh, for mid-trigger relief (E). The upper trigger needs no abduction (F); the lower trigger requires a little adduction (G).



Low right ilium: The posterior superior spine is lower on the right. Treat the patient in a supine position, using the trochanter or pubic trigger. The thigh is flexed about 135 degrees on the hip; usually about a 20 degree abduction of the thigh is required, and slight medial turning in of the leg on the thigh.

Right oblique, sacroiliac: The trigger here is on right side of posterior surface of sacrum. (1) Heavy pressure (40 pounds) is applied over the base of sacrum on the left side. (2) Heavy pressure is applied near the apex of the sacrum. (3) Apply pressure as in (1), but over the right side of the base.

Right fifth lumbar: (1) This technique is for the lower trigger. The patient is prone. Find the trigger under posterior superior spine. Hang the patient's right thigh vertically off the side of the table; the doctor holds the leg a few inches below the knee and abducts the leg on thigh moderately (B). (2) For the upper fifth lumbar trigger, the technique is the same except that the pull is on the other leg and side bending is in the opposite direction (J). (See Figure 5.) (3) This technique involves simple rotation, as in fourth lumbar, R or L. (4) This technique is used in lordotic spines. The patient is prone; the doctor stands at the left and places his right foot on the near edge of the table, reaches across, and lifts the patient's right leg onto the doctor's thigh just below patient's knee (GL).

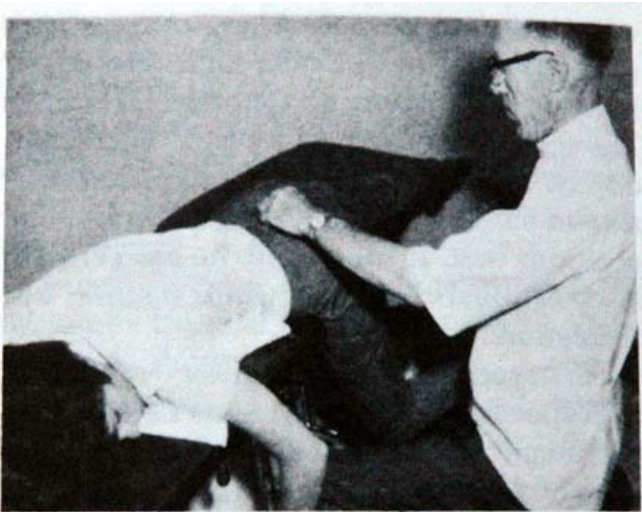

Fig. 5 A demonstration of the technique used for the upper trigger of the fifth right lumbar vertebra (J).

Right fourth lumbar: (1) This is similar to the fifth lumbar upper trigger technique. (2) The patient is prone; the doctor stands at the left side and reaches across to grasp the patient's anterior ilium. He rotates the patient's pelvis about 45 degrees, and leans back so that his body weight does the work (L). (3) This technique is like (4) in fifth lumbar correction.

Third lumbar: (1) This is opposite of (2) for fourth lumbar (R) correction. (2) This is like (4) for fifth lumbar correction.

Third, fourth, or fifth lumbar with lordosis or definite spondylolisthesis: (1) The patient is in a prone position with the doctor at his left side. The doctor puts his right foot on the table and raises the patient's right leg up about 30 degrees and toward him, until the pelvis is rotated about 30 degrees (GL). For spondylolisthesis, repeat from the opposite side (ER).

Right second lumbar: The patient is in a supine position. Find the trigger point in from of the right ilium near middle of inguinal ligament to the lower end. Bend thighs to a little above vertical, with knees bent. Rotate the pelvis toward the left side of the patient's body, and side bend toward the left to the point of trigger relief (JR). Support the top ilium against excess adduction of the flexed thigh by a forward pull on the top of the ilium.

Right first lumbar, and eleventh and twelfth thoracic: The patient is supine, with a folded pillow beneath the lower lumbar area. In marked antexion, thighs are flexed to about a 45-degree angle with the body. Then the knees are brought slightly to the patient's right and feet slightly toward the patient's left (KL). A variation would be opposite rotation (KR) (Fig. 6).

Right tenth and eleventh thoracic: (1) With the patient prone, the doctor, at the patient's right, grasps the left anterior superior spine by reaching over the right side. He rotates the pelvis to a point of trigger release (about 45-degrees) (R). The trigger here is paravertebral. (2) This technique is like that used for correction of the seventh, eighth, and ninth thoracic, right.

Right seventh, eighth, and ninth thoracic: The patient is prone, arms hanging off the table, and the doctor is at the left side. He raises the patient's right arm up beside his head, holds the arm near the axilla, rotates the upper chest to the right, and side bends to left (RI).

Eighth and ninth flexion lesion: The patient is prone, with a large pillow folded under the lower half of the sternum. The doctor lifts up on either shoulder and rotates (BR or JL) (Fig. 7).

Right fifth and sixth thoracic: (1) This technique is as in seventh, eighth, and ninth thoracic correction. (2) The doctor is on the right side. He reaches across to left shoulder; the patient's

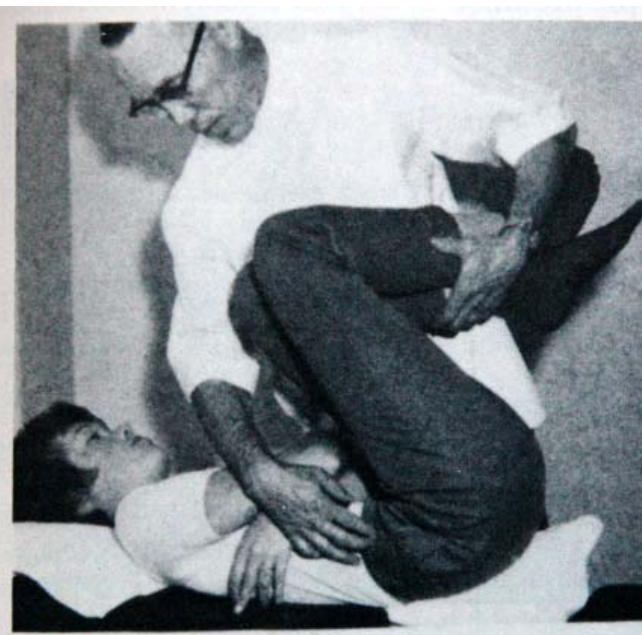
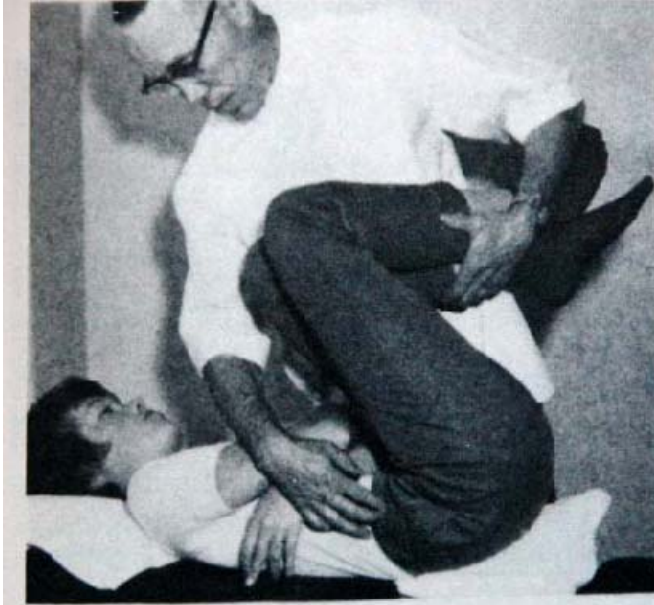

Fig. 6 A demonstration of a technique for right twelfth thoracic correction (KR).

right arm is up beside his head, or at least hanging more cephalad, and the left arm is hanging. He pulls the left shoulder back and around caudad (JL).

Right fourth and second thoracic: The patient is prone, arms hanging. The doctor's hand is placed on the patient's chin and cheek. He bends the neck backward, to the left, and rotates slightly to the right (GR). Variations include left rotation (GL), and right side bending (ER or EL).

Right third thoracic: Raise the patient's right arm beside the head, rotate, and side bend the head and neck toward the left, letting the head hang partly off the table in flexion of the upper thoracic area. Elevate the right shoulder in posterior direction, with the doctor's arm under the patient's axilla (JL).



*Fig. 6 A demonstration of a technique for right twelfth thoracic correction (KR).*

side of the prominent tender spinous process of the second cervical vertebra, with fairly marked forward bending (AL). (2) An alternative is the same except for opposite rotation (AR).

First and second cervical: (1) Correction usually is attained with the patient in marked backward bending and with slight side bending and mild rotation as indicated by diagnosis and comfort (ER or EL) (GR or GL) (Fig. 8). (2) An alternative is marked rotation as indicated, with no bending (L) or (R).

Shoulder joint: Frozen shoulder may be eased beyond aid obtained by upper thoracic and lower cervical corrections by finding an arm position which relieves the tender spot in the shoulder (see trigger points). Shoulder stiffness with trigger 2, 3, and 4 are relieved in the prone position with the elbow behind the midline with abduction varying from 80 to 0 degrees (Fig. 9). Trigger 1 usually is relieved in a supine position with the upper arm vertical and the forearm halfway between cephalad position and across the shoulder girdle. Ten pounds of pressure are applied downward through upper arm and shoulder. Both may be further improved by traction in a caudad direction, usually with 30-degree abduction, occasionally adducted, across chest following corrections above.

Acromio-clavicular: The upper are is fully abducted and the forearm cephalad.

Elbow, right radial head: Usually supination is used; occasionally some abduction or adduction are necessary. (Tenderness of the lateral epicondyle indicates probably a first thoracic or first rib lesion.)

Wrist, thumb, and other fingers: All can be easily relieved by finding tender spots and locating the position of release. The thumb is usually bent backward and rotated. Tenderness is near the metacarpophalangeal joint or the carpometacarpal joint.

Knee: The medial meniscus is nearly always relieved by internal rotation of the extended leg on the thigh, usually with slight flexion and adduction (Fig 10). The lateral meniscus usually requires external rotation.

Feet: ankle sprains: There is tenderness ½ inch below the malleolus, usually a little anteriorly. This usually is relieved by inversion of the foot with external rotation, occasionally by eversion or dorsiflexion. An ankle sprain is an osteopathic lesion and can be treated in this manner, giving much relief.

Right first thoracic: Extend, side bend, and rotate to the right (DR). This is irregular; it may be necessary to side bend left (HR).

Right eighth cervical: The patient is in a supine position. Mild forward bending, rotation, and side bending away from lesioned side are applied. (Palpate the transverse process in the side of the neck) (JL).

Sixth and seventh cervical: The patient is in a supine position; head off end of the table. Back bending, side bend away and rotate toward the side of lesion or as indicated by the position of spinous process (GR). For seventh cervical lesions, rotate left (GL).

Fifth cervical: This technique is similar to that for eighth cervical correction except that more forward bending is used; it may be necessary to reverse sides (KL).

Fourth cervical: (1) This area frequently is either back bending or spondylolisthesis. Lesions are corrected in marked backward bending and slight side bending as indicated. Check progress by the tender transverse process (GR). (2) Use rotation and side bending to the same side without any back bending (IL). Try the opposite if the first attempt fails (CR).

Third cervical: (1) Use side bending and rotation toward the

Calcaneus: There is tenderness beneath the proximal head; this usually is corrected in eversion or outward rotation of heel on foot.

Cuboid: There is tenderness beneath it. There is eversion of the lateral side of the foot with moderate dorsiflexion.

Navicular: Inversion and a little internal rotation of front foot, with some dorsiflexion.

Fibula, proximal head: (1) One method is similar to the treatment for ankle sprain. (2) It may be held forward by thumb pressure.

Bunion: There is tenderness at lateral sesamoid, which is relieved by flexion, abduction, eversion of the great toe until sesamoid tenderness is relieved.

Right ribs: (1) The patient sits with his back to the doctor. The doctor's left foot is on the table, with a pillow on the doctor's knee. The patient drapes his left arm over the pillow, tilts his pelvis to the left, puts his feet at the right side of his hips. The position is marked right side bending, moderate forward bending, and right rotation. It takes 1 to 2 minutes to achieve the necessary relaxation. The position is (BR), or rarely, the opposite rotation (BL). (2) The patient lies on his left side, with his thighs flexed 90 degrees and his right arm hanging behind him. The doctor stands behind and holds the patient's head forward, side bent, and rotated right, and presses caudad on the right shoulder (BR).

Fifth, sixth, seventh, and eighth ribs: Use a folded pillow under left shoulder.

## GENERAL RULES

1. Treat "hot lesions first.
2. Straighten the patient out slowly enough that he can remain relaxed. He will resist and tense if rushed.
3. Check for relief of pain after correction, if only to demonstrate its absence to the patient.
4. An especially "dry" lesion will sometimes be tender after correction. A minute's traction will ease it.
5. Patients will try to help you. Don't let them.

## SUMMARY

Osteopathic spinal and appendicular lesions occur in positions more eccentric than that found by the examining physician. They are in a state of strain because the natural position of the patient holds him away from the eccentric position. The strain is relieved by exaggerating the deformity found upon examination. The lesions will release and correct spontaneously if held relaxed in the exaggerated position of 1 ½ minutes. The correction itself is restful and comfortable.

Grateful acknowledgment is given to many who have contributed techniques or ideas, in particular: Harry Davis, D.O., deceased; G.E. Holt, D.O., Pendleton, Ore.; Hugh Barr M.D., Penticton, B.C.; Annabelle F. Thorne, D.O., San Francisco, CA; Margaret W. Barnes, D.O., Carmel, CA; Carl L. Fagan, D.O., Monterey, CA; James E. Spencer, D.O., Palo Alto, CA; Melvin Hennigson, D.D.S., Hayward CA; Rollin E. Becker, D.O., Dallas, TX; Harold V. Hoover, D.O., Tacoma, WA; T.J. Ruddy, D.O., Los Angeles, CA; Harold S. Saita, D.O., Vancouver, B.C.; and Paul K. Theobald, D.O., Oakland, CA.